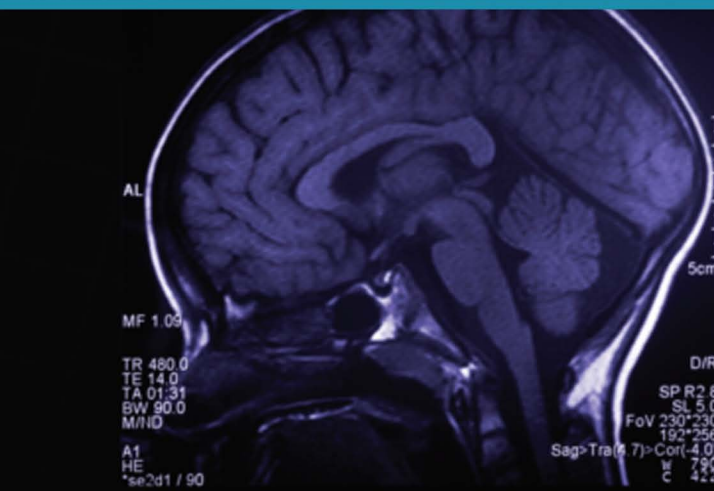
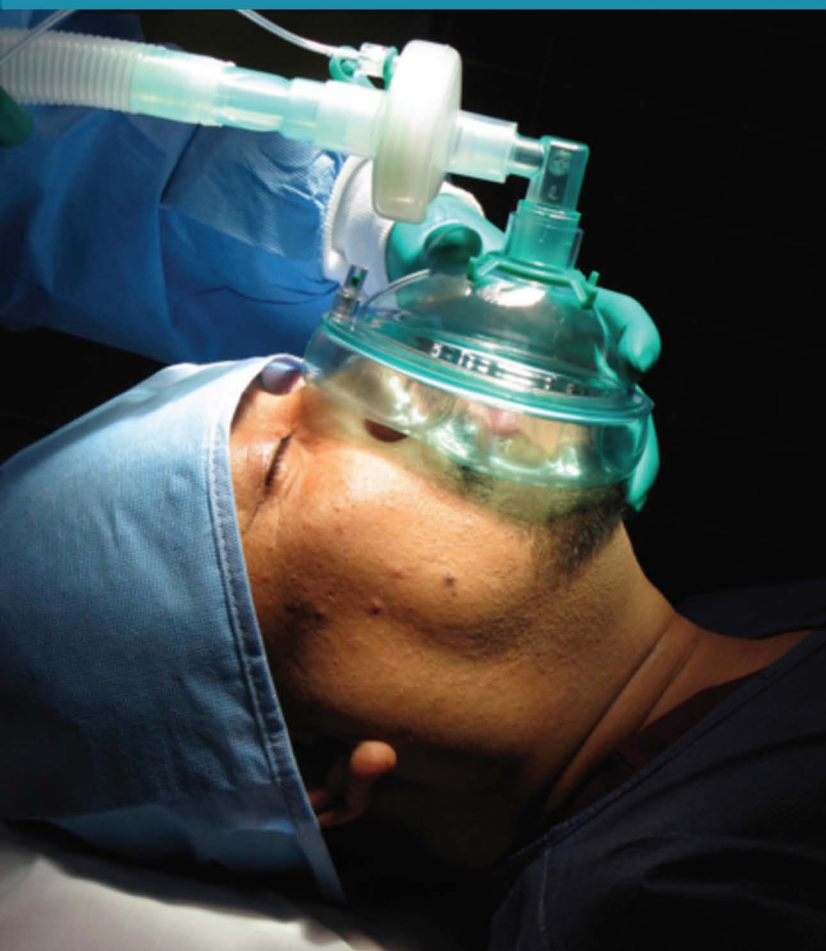

# Medical Gas Research



MEDICAL GAS RESEARCH



# Ozone therapy in conjunction with oral antibiotics as a successful primary and sole treatment for chronic septic prosthetic joint: review and case report

Robert Jay Rowen\*

Private Medical Practice, Santa Rosa, CA, USA

\*Correspondence to: Robert Jay Rowen, M.D., drrowen@att.net.  
orcid: 0000-0002-5717-5720 (Robert Jay Rowen)

## Abstract

The world is facing crisis in management of infectious diseases. The mainstay of treatment has been chemical anti-infectives. These drugs are failing, as superbugs emerge and medicine becomes more sophisticated with treatments such as prosthetic devices, which can harbor bacteria protected by biofilm. This case report describes a 68-year-old woman who received bilateral artificial hips on October 27, 2015. The right hip prosthesis subsequently became septic by June 2016. Three orthopedic surgeons offered her a several month program, which included removal of the prosthesis, implantation of an antibiotic impregnated “spacer” and months of intravenous antibiotics. Instead, she sought and received intravenous ozone therapy, local joint ozone gas injection, and nutritional supplements. She quickly improved. Subsequently, she was given oral Augmentin (875 mg three times daily) beginning at September 19, 2016 for 1 month, when a third culture returned positive for two oral organisms. She experienced even more rapid improvement. By October 12, she reported total resolution of symptoms. A subsequent MRI on November 30, 2016 showed total clearance of infection. This is the first report of a septic prosthetic joint infection completely resolving without some form of surgical intervention, debridement at the least. It is also the first to report such cure without the use of any parenteral antibiotics. This case and world literature suggest that ozone therapy could be considered as a useful adjunctive treatment for hard to treat infection and biofilm.

**Key words:** ozone therapy; septic joint; antimicrobial; infected prosthesis; antibacterial synergism; biofilm; antibiotic resistance; immune modulation

doi: 10.4103/2045-9912.235139

**How to cite this article:** Rowen RJ. Ozone therapy in conjunction with oral antibiotics as a successful primary and sole treatment for chronic septic prosthetic joint: review and case report. *Med Gas Res.* 2018;8(2):67-71.

## INTRODUCTION

Ozone (O<sub>3</sub>) is an allotrope of oxygen. It is the strongest naturally occurring oxidant. It is produced in nature by lightning, or ultraviolet irradiation. Medical ozone gas is created with a corona high arc discharge.

A succinct summary of ozone history and use can be found in the review by Elvis and Elka.<sup>1</sup> Nikola Tesla patented (U.S. patent 568177) the first commercial ozone generator. Passing medical grade oxygen through the discharge makes medical oxygen/ozone gas. The mixture is 1–5% ozone and 95–99% oxygen, which is the “ozone” used for treatment. Germans doctors in the trenches used ozone to disinfect wounds during World War I.

German doctors expanded the world of ozone by introducing ozone to treat blood, either by direct gas administration or removing 50–200 mL blood, adding ozone gas, and returning it to the patient’s circulation.

Basic published research from Italy<sup>2</sup> and Cuba<sup>3</sup> has led to publication of books containing their peer-reviewed studies. Both researchers have independently confirmed: 1) immune system modulation balancing its inflammatory/anti-inflammatory cytokines, 2) increase in production of red blood cell (RBC) 2,3 diglycerophosphate (DGP) (greater oxygen release), and improved rheological properties of blood (increased red cell flexibility), 3) elevation of key anti-oxidant enzymes such as superoxide dismutase (SOD), and 4) increased glutathione

achieving improved redox cell balance. Part of these effects is generated through ozone’s creation of reactive oxygen species and lipid oxygenation products. There is no chemical residue left behind as in the case of drug metabolites, as ozone is oxygen.

When white blood cells encounter infection, they undergo a “respiratory burst” and consume up to 50× more oxygen than at rest, and produce powerful germicidal oxidants.<sup>4</sup> Clearly access to abundant oxygen in infection is a must for immune system success.

Menendez’s group has gone further in the field of infection. In a series of articles, they found: 1) Simply preconditioning rats with intraperitoneal ozone gas followed by intraperitoneal injection of a lethal amount of microbes from fecal material increased the survival of the animals from 0% (controls) to 33%. When the antibiotic combination of Tazobactam/Piperacillin was added, survival increased to 93%.<sup>5</sup> 2) Ozone preconditioning (absence of any other treatment) of rats improved the survival of a subsequent lethal injection of fecal material into the peritoneum up to 62.5%.<sup>6</sup> 3) Ozone preconditioning of rats induced reduced levels of tumor necrosis factor alpha (TNF-α) production when the rats were later subjected to induced sepsis by fecal material.<sup>7</sup>

Directly germicidal, ozone kills 99% of bacteria in seconds and is 100× more effective at destroying bacteria than bleach.<sup>8,9</sup>

Our body produces abundant oxidants to hurl at invading pathogens, such as hydrogen peroxide, superoxide, hypochlo-

rite, and singlet oxygen. Scripps reported a revolutionary discovery that our bodies also produce ozone as part of immune defenses.<sup>10</sup> Ozone therapy has been reported to prevent drug resistance by *M. Tuberculinum*.<sup>11,12</sup>

Ozone therapy is not merely antibacterial. Ozone inactivates many viruses including polio, Norwalk, coliphage MS2, hepatitis A and others.<sup>13-16</sup> In 2015, four cases of acute Ebola (Sierra Leone outbreak of 2014–2015) were treated with ozone therapy. All four fully recovered within 2–4 days without clinical deterioration after commencement of treatment. The death rate otherwise was about 60% no matter what treatment was provided.<sup>17</sup> (After publication, I learned that our 5<sup>th</sup> case, which we believed at the time was prophylactic treatment for Ebola, was actually symptomatic at the time of treatment. “Chance” odds of these results would be less than 1%.) None of the cases experienced long-term complications.

Ozone therapy is exceptionally safe—complication rate of only 0.7 per 100,000 treatments, and virtually all such complications result from improper administration.<sup>18</sup>

The foregoing suggests that ozone therapy might provide help and answers to the growing crisis of drug resistant infection and hard to treat infections. The objective of this report is to demonstrate ozone therapy as a potential solution for these challenging cases.

## PROSTHETIC JOINT INFECTIONS

“Prosthesis-related infection is a serious complication for patients after orthopedic joint replacement, which is currently difficult to treat with antibiotic therapy... Evidence indicates that prosthesis infections are actually biofilm-correlated infections that are highly resistant to antibiotic treatment and the host immune responses.”<sup>19</sup>

Cobo et al.<sup>20</sup> reports that prosthetic joint infections are notoriously hard to treat. They may require removing the prosthesis, leaving a flail limb until replacement after a protracted course (3–6 months) of intravenous antibiotics. They had significant success with non-joint replacement with a combination of intravenous (IV)/oral antibiotic. However, all patients received some form of surgical/debridement therapy. There is also a significant failure rate. Disability and cost can be considerable.

Bernard et al.<sup>21</sup> reported that a shorter course of 6 weeks of antibiotics with at least one week of IV therapy successfully cured 80% of infected prosthetic joints. However, all 144 cases required surgery.

Bjarnsholt described the difficulties in treating biofilm infection.<sup>22</sup> Biofilms are considered a new category of infection, growing in “slime-encrusted” aggregates. These infections, such as catheter and implants affect millions each year with many deaths. Acute infections involve planktonic bacteria, usually treatable with antibiotics, although successful treatment depends on accurate and fast diagnosis. But if bacteria form a biofilm, the infection often is untreatable and becomes chronic. Ozone has shown promise in treating bacterial biofilms.<sup>23</sup> It is extremely effective in the gaseous form in cutting through the polysaccharide matrix quickly.<sup>24</sup> In the current case, ozone gas was administered directly into the infected joint. Perhaps ozone is capable of destroying the biofilm’s sessile aggregates (described by Bjarnsholt<sup>22</sup>), and returning

the bacteria to their planktonic form, becoming susceptible once again to standard drug therapy.

Ozone has a long European history of use in joints and this treatment has recently caught on in conventional medicine. Trevisani and Udell<sup>25</sup> presented an abstract at the American College of Rheumatology annual meeting (2015) demonstrating “surprising” and very significant Osteoarthritis Index score results ( $P < 0.001$ ) with ozone instillation into osteoarthritic knees.

Ozone therapy has many modes of administration. It is often administered by direct intravenous gas (DIV), or by a method called major autohemotherapy (MAH). MAH is the most common form of ozone delivery amongst members of medical ozone organizations. Blood is withdrawn into a bottle or plastic bag under gravity, heparinated, and an equal volume of oxygen/ozone gas mixture is added and the combination gently mixed and returned under gravity. With DIV, the oxygen ozone gas mixture is slowly administered by direct IV injection. This method, being far less expensive, is very commonly administered worldwide amongst ozone practitioners.

Treatments relevant to this case include direct intra-articular injection of ozone gas and treatment of blood. The former is to expose the entire joint space contents to the beneficial effects of ozone gas. The latter is to augment the inherent immune defenses of the body, and enhance circulation and oxygen utilization.

Advancement in the MAH method of therapy is the method of hyperbaric ozone therapy (HBO<sub>3</sub>). In the present case, therapy was administered by HBO<sub>3</sub>. In this method, 200 mL of patient’s blood is withdrawn from a peripheral vein into a vacuum glass flask and heparinated. Oxygen ozone gas mixture, 200 mL, is generated at an ozone concentration of 70 µg/mL. The gas is pumped into the bottle under pressure [average = 1.9 atmospheres absolute (ATA; 2.066 kg/cm<sup>2</sup>)]. This pressure maintained by additional oxygen. The blood is then returned rapidly to the patient. This constitutes “one pass” and delivers 14,000 µg of ozone. Austrian physician Johann Lahodny, MD pioneered a higher dose method and termed it “ozone high dose therapy” or “OHT”. The treatment is repeated 9 more times for a total of 10 “passes” and delivery of 140,000 µg ozone. OHT is commonly known as “10 pass” in the USA. The MAH method does not have the benefit of pressurized oxygen gas in the blood filled bottle.

## CASE REPORT

The patient was a 68-year-old white female who underwent bilateral hip replacement surgery on October 27, 2015 for “bone on bone” arthritis. Her recovery process was unremarkable except for lingering discomfort in her right hip. By June 2016, however, the vague discomfort progressed into intermittent pain and swelling of the hip. By mid July 2016, the pain and swelling remained 24/7, and, she developed an intermittent limp. She had to drastically curtail her exercise and yoga. Three separate orthopedic specialists diagnosed joint infection by magnetic resonance imaging (MRI). All told her she would need removal of the prosthetic joint and months of intravenous antibiotic therapy, with an antibiotic impregnated joint spacer. She was terrified of this prospect, causing her to





travel 400 miles to our office for ozone therapy. Her history also included 20 root canal restorations in her jaws.

MRI scan showed “very marked synovial thickening/effusion” around the joint which significant edema in the joint and surrounding muscles. She also had osteolysis in Gruen zones #1, #3, #6, and #7. Complete blood count and blood chemistry were unremarkable. Two initial joint aspiration cultures taken by her treating specialists (August 18 and 24, 2016) were negative. This is not necessarily surprising. Even the Mayo Clinic has observed a large number of septic prostheses inclusive of sinus tracts which were both aerobic and anaerobic culture negative.<sup>26</sup> Her surgeons still strongly steered her towards prosthesis removal.

She presented to us on August 30, 2016. Pertinent physical findings included temperature of 37.3°C, significant swelling in the entire right hip area, with the physical presence of deep tissue fluid. Her hip range of motion was good on each side. White blood count was 7780 with normal differential. Erythrocyte sedimentation rate: 34 mm/hour. Free Triiodothyronine and thyroid stimulating hormone were both normal. Blood chemistry (electrolytes, kidney and liver functions tests) was unremarkable.

An incidental but important physical exam finding was detection of a disturbance in tooth number 6, right upper canine, which had undergone previous endodontic treatment (root canal).

After informed consent was obtained from the patient, she received a single 20 mL of ozone gas, 47 µg/mL, into the right hip (after 1.5 mL 1% preservative free procaine for local anesthesia). This was followed by intravenous HBO<sub>3</sub>, 140,000 µg “10 pass” ozone as previously described. We performed 3 more HBO<sub>3</sub> treatments (140,000 µg) on August 31, September 1, and September 2 before she returned to Los Angeles area, USA.

Additionally, I recommended her for specific radiological evaluation of tooth number 6. The exam later returned with a confirmation of the suspected cavitation/infection.

Upon returning to Los Angeles area, she had two more similar ozone treatments on September 6 and 13.

By September 19, she was called by her orthopedist with confirmation of a positive third culture taken on September 14, 2016. The organisms were 1+ *Viridans streptococcus* and 1+ *Rothia mucilaginosa* (both oral bacteria).

When this culture returned, she was prescribed oral Augmentin 875 mg twice daily. She began it immediately, and was told emphatically that she needed immediate revision joint surgery as described above.

In the meantime, she had MRI of her jaws revealing 2 suspicious restorations, including number 6. She had root canal revision surgery on these teeth on October 8 and November 10, 2016.

She discontinued oral antibiotic therapy after 4 weeks (although she took a prescribed dose in conjunction the days of the oral root canal surgeries). She reported continuing hyperbaric ozone treatments on October 11, 18, 26, November 3, 9 and 13, with final treatment on December 6, 2016. In all, she had 13 HBO<sub>3</sub> treatments delivering 140,000 µg ozone each session, and one intra-articular injection.

The following is her clinical summary in her own words

(unchanged) sent by email: “I felt an immediate improvement of the pain and swelling one week after the four 10-Pass IV Ozone treatments at Dr. Rowen’s clinic. (For the first 3 days after the [hip] ozone injection, the swelling and pain worsened, and then it subsided to an improved state.) (Author note – this could be attributed to the temporary extra volume (gas) in the joint from the injection as well as reaction to the necrotic waste products released as the heavy bacterial load died off.) On Sept 21, two days after starting Augmentin, the swelling and pain around the infection went down about 80%, very substantial. It was an immediate reaction to the medication, which according to both Dr. K and Dr. P, is never expected from oral Augmentin... especially to have such an extreme improvement so quickly. I believe that my having had six 10-Pass IV Ozone treatments already completed before I started the Augmentin, boosted the effects of the drug and the healing. I started feeling that the infection was completely gone, and have had no signs of swelling or pain, since October 12. However, I decided to wait a few weeks before re testing. I had another MRI of my right hip done on Nov 30, 2016 that showed the infection was completely gone. The doctor at the MRI lab, Dr. M, could not believe it was the same patient and actually called my surgeon, Dr. P, to ask if he had done a revision surgery and had “washed it out”. I also had X-rays and a new blood test at Dr. P’s office on December 2. All of the new tests show that I am infection free. I am now 12½ weeks post the Augmentin course I took, swelling and pain free, taking 1 to 2 mile speed walks on sand, as well as back to my 4X weekly Bikram yoga classes. I intend on continuing the 10-Pass IV Ozone treatments once a month for the next year.”

Her hip MRI taken on November 30, 2016 showed significant to complete resolution of all abnormalities of her previous scan. There remained “mild residual edema signal and changes of osteolysis involving Gruen zones #1 and #7.” Her treating orthopedic physicians were satisfied that the infection was cured. As of February 1, 2018, she remained asymptomatic.

## DISCUSSION

The patient was terrified of the definitive recommendation of her surgeons to remove the prosthesis for months, leaving her with a flail leg and receive massive doses of antibiotics and sought any reasonable alternative. Her ultimate progress closely mirrors the ozone/antibiotic potentiation found by Bette in animals.<sup>5</sup>

This case illustrates the exceptional utility of ozone, one of the oxidative therapies, in the treatment of infection, and likely significant synergism with conventional therapy. Other oxidation therapies include ultraviolet blood irradiation therapy, intravenous hydrogen peroxide, and high dose intravenous vitamin C. A summary of published anti-infective utility of these sister therapies was published in our report on Ebola.<sup>17</sup> Hyperbaric ozone therapy offers a significant advantage over conventional MAH. The laws of physics (Henry’s law of solubilized gases<sup>27</sup>) provide that oxygen, at a pressure of 2 ATA will result in about 4.4 mL of dissolved oxygen gas per 100 mL of blood. Ten passes of 200 mL blood carrying an oxygen/ozone gas mixture at 2 ATA will then deliver about 88 mL of dissolved oxygen gas in total. We are using an average of 1.9 ATA, just slightly less.



Whilst the common medical concept of intravascular gas administration is negative (concern about “air” embolism), there is an abundance of articles in the medical literature documenting significant benefits to this practice, long performed<sup>28</sup> in Europe, using up to 50 mL of oxygen gas, at 1–2 mL per minute. Oxygen is not “air”. It is metabolically active and rapidly consumed. The “10 pass” HBO<sub>3</sub> described takes about an hour. Hence, its delivery of oxygen gas (dissolved), about 88 mL over this time period is about 1.3 mL per minute, and well within the parameters of oxygen gas administration used in Europe.

Schmidt<sup>29</sup> reported, “Apart from the general improvement in oxygen availability, IV oxygen therapy causes eosinophilia, which can be valued as an increase in undetermined cellular immunological resistance. Furthermore, rheological qualities of the blood as well as diuresis are improved, the release of oxygen into the tissue is increased, and the blood pH is normalized. Compared with hyperbaric oxygen therapy, IV oxygen therapy seems to have less side effects. Application is less complicated, less expensive but probably of higher efficacy.” Intravenous oxygen gas also improves the thromboxane/prostacyclin ratio,<sup>30</sup> which would be expected to result in better blood flow and reduction in inflammation.

HBO<sub>3</sub> may provide one additional unexpected benefit. It might actually mimic the benefit of actual hyperbaric oxygen (HBO). Thom reports: “Principle mechanisms of HBO [in promoting healing] are based on intracellular generation of reactive species of oxygen and nitrogen.” “It is well accepted that oxygen at greater than 1 ATA increases the production of these species.”<sup>31</sup> This hyperbaric ozone method generates up to 2 ATA oxygen in the treated blood. Hence, beneficial molecular signaling molecules generated by HBO could also be generated by the HBO<sub>3</sub> method.

The world is facing a crisis in management of bacterial infection. While the offending germs in this case were of oral source, which are usually sensitive to antibiotics, it is highly unusual, if not regarded impossible, for a closed space infection, essentially an abscess, to be cured without surgical intervention such as drainage and debridement, which would be necessary for mechanical removal of biofilm. Foreign material (prosthesis) makes matters much worse.

Ozone therapy promises a potential breakthrough in the management of all infection by its modulation of the immune system, improvement in oxygenation, direct antiseptic effects on virtually every microorganism, and ability to cut through biofilm. Mammalian cells, aerobic, have novel ways to resist oxidative damage, and actually respond by producing higher levels of SOD and catalase (Bocci and Menendez). Bacteria and viruses lack these mechanisms. Hence, despite over 120 years of continuous use, we have never seen resistance, against the germicidal ultraviolet light, hydrogen peroxide, bleach and ozone for disinfection.

The value of ozone synergism in treating prosthetic joint infections could obviously save significant morbidity and cost. Dr. Cobo<sup>32</sup> specified, “only acute early postoperative early diagnosed” infections should be offered “DAIR” therapy (debridement, antibiotics and implant retention),

and emphasized the importance of surgical debridement. IV antibiotics are administered the first week. (Given time, the organisms will set up a biofilms community. Hence, there is the need to diagnose and treat early for conventional approaches.)

A summary of the seriousness of biofilm infection challenges details that these often culture negative infections may require direct microscopy or DNA molecular methods for confirmation. They now affect 17 million Americans yearly, and result in some 450,000 deaths. Meticulous surgical debridement and high dose local application of implanted antibiotics are the mainstay.<sup>33</sup>

The instant case was longstanding, and nearly a year after surgery. It required neither surgery nor IV antibiotics for resolution, apparently a medical first.

Ozone therapy cannot be patented. Accordingly, this modality greatly suffers from lack of profitability, which would otherwise encourage an entity (company) to conduct the highly expensive studies that would be necessary for the treatment to gain lucrative (for a patentable drug) Food and Drug Administration (FDA) approval. (The Sierra Leone Ebola patients were treated by DIV ozone gas, costing less than 5 USD in materials, excluding the ozone generator.) But, such advances are desperately needed, as the medical world is highly reluctant to use anything that has not received FDA approval.

The Trevisani/Udell knee ozone abstract<sup>25</sup> was flagged as being one of the most interesting presented at the American College of Rheumatology meeting. Yet in today’s medical world, it is rare to see studies on a modality that will not bring a hefty profit to industry. Hence, at this time, ozone is relatively unknown to the conventional medical world, despite thousands of health practitioners worldwide utilizing the remarkable therapy.

This case is the first reported cure of a septic prosthetic joint without surgery or intravenous drugs. Ozone therapy could be considered in conjunction with conventional antibiotics in the treatment of challenging infection.

Ozone therapy has been reported to cure human infection. *In vivo* animal studies strongly suggest that ozone therapy could be synergistic in combination with antibiotic therapy. Ozone therapy appears to have been a highly adjunctive therapy for this case of septic prosthetic hip. It provided the patient significant initial improvement, and then, in conjunction with a very “mild” oral-only conventional anti-infective treatment, participated in a total cure. With the ongoing “call to action”<sup>34</sup> in the rapidly losing war against infection, synergistic therapies (including safe unconventional methods), regardless of commercial profitability, need to be considered for sick patients, regardless of regulatory approval, and, intensively studied if we are to save lives and reverse the tide.

#### Acknowledgements

Dedicated to the tireless efforts of researchers and clinicians alike to aid a remarkable therapy in overcoming the “tomato effect”.

#### Author contributions

Robert Rowen 100%.

#### Conflicts of interest

None.

#### Financial support

None.



### Institutional review board statement

Fully informed consent in accordance with the laws of the State of California regarding unconventional medical therapy was obtained.

### Declaration of patient consent

The author certifies that he has obtained patient consent form. In the form, the patient has given her consent for their images and other clinical information to be reported in the journal. The patient understand that her name and initials will not be published and due efforts will be made to conceal their identity, but anonymity cannot be guaranteed.

### Copyright transfer agreement

The Copyright License Agreement has been signed by the author before publication.

### Data sharing statement

Datasets analyzed during the current study are available from the corresponding author on reasonable request.

### Plagiarism check

Checked twice by iThenticate.

### Peer review

Externally peer reviewed.

### Open access statement

This is an open access journal, and articles are distributed under the terms of the Creative Commons Attribution-NonCommercial-ShareAlike 4.0 License, which allows others to remix, tweak, and build upon the work non-commercially, as long as appropriate credit is given and the new creations are licensed under the identical terms.

### Open peer review report

**Reviewer:** Wen-Wu Liu, Secondary Military Medical University, China.

**Comments to author:** In this paper, the authors reported a case of chronic prosthetic joint infection which was successfully treated with ozone. The author also described the use of ozone therapy in medicine.

## REFERENCES

- Elvis AM, Ekta JS. Ozone therapy: a clinical review. *J Nat Sci Biol Med.* 2011;2:66-70.
- Bocci V. *A New Medical Drug 2<sup>nd</sup> ed.* Netherlands: Springer; 2011.
- Menendez S, Weiser M. Advances of ozone therapy in medicine and dentistry. 2016; Havana, Cuba.
- Babior BM. The respiratory burst of phagocytes. *J Clin Invest.* 1984;73:599-601.
- Bette M, Nüsing RM, Mutters R, Zamora ZB, Menendez S, Schulz S. Efficiency of tazobactam/piperacillin in lethal peritonitis is enhanced after preconditioning of rats with O<sub>3</sub>/O<sub>2</sub>-pneumoperitoneum. *Shock.* 2006;25:23-29.
- Rodríguez ZZ, Guanche D, Alvarez RG, Rosales FH, Alonso Y, Schulz S. Preconditioning with ozone/oxygen mixture induces reversion of some indicators of oxidative stress and prevents organic damage in rats with fecal peritonitis. *Inflamm Res.* 2009;58:371-375.
- Zamora ZB, Borrego A, López OY, et al. Effects of ozone oxidative preconditioning on TNF- $\alpha$  release and antioxidant-prooxidant intracellular balance in mice during endotoxic shock. *Mediators Inflamm.* 2005;2005:16-22.
- Leusink J, Kraft G. Antimicrobial effects of ozonated water against generic E.coli on swine intestines varying ozone concentrations and exposure times. [https://www.ozonesolutions.com/files/research/ecoli\\_swine\\_intestines.pdf](https://www.ozonesolutions.com/files/research/ecoli_swine_intestines.pdf).
- Fact Sheet Disinfection Using Chlorine Bleach. <http://www.environmentize.ca/wp-content/themes/Environmentize/images/chlorinefact-sheet.pdf>.
- Babior BM, Takeuchi C, Ruedi J, Gutierrez A, Wentworth P Jr. Investigating antibody-catalyzed ozone generation by human neutrophils. *Proc Natl Acad Sci USA.* 2003;100:3031-3034.
- Belianin I, Shmelev EI. Blood ozonation in the treatment of patients with progressive pulmonary tuberculosis concurrent with diabetes mellitus. *Probl Tuberk.* 1998;30-33.
- Belianin I. The action of blood ozonation on the course of progressive pulmonary tuberculosis combined with diabetes mellitus. *Ter Arkh.* 1997;69:44-48.
- Kekez MM, Sattar SA. A new ozone-based method for virus inactivation: preliminary study. *Phys Med Biol.* 1997;42:2027-2039.
- Shin GA, Sobsey MD. Reduction of Norwalk virus, poliovirus 1, and bacteriophage MS2 by ozone disinfection of water. *Appl Environ Microbiol.* 2003;69:3975-3978.
- Herbold K, Flehmig B, Botzenhart K. Comparison of ozone inactivation, in flowing water, of hepatitis A virus, poliovirus 1, and indicator organisms. *Appl Environ Microbiol.* 1989;55:2949-2953.
- Emerson MA, Sproul OJ, Buck CE. Ozone inactivation of cell-associated viruses. *Appl Environ Microbiol.* 1982;43:603-608.
- Rowen R, Robins H, Carew K, Kamara M, Jalloh M. Rapid resolution of hemorrhagic fever (Ebola) in Sierra Leone with ozone therapy. *Afr J Infect Dis.* 2016;10:49-54.
- Jacobs M. Zwischenfälle und typische Komplikationen in der Ozon-Sauerstoff-Therapie. *Naturheilpraxis.* 1982;3:444.
- Song Z, Borgwardt L, Høiby N, Wu H, Sørensen TS, Borgwardt A. Prosthesis infections after orthopedic joint replacement: the possible role of bacterial biofilms. *Orthop Rev (Pavia).* 2013;5:65-71.
- Cobo J, Miguel LG, Euba G, et al. Early prosthetic joint infection: outcomes with debridement and implant retention followed by antibiotic therapy. *Clin Microbiol Infect.* 2011;17:1632-1637.
- Bernard L, Legout L, Zürcher-Pfund L, et al. Six weeks of antibiotic treatment is sufficient following surgery for septic arthroplasty. *J Infect.* 2010;61:125-132.
- Bjarnsholt T. The role of bacterial biofilms in chronic infections. *APMIS Suppl.* 2013:1-51.
- Bialoszewski D, Pietruczuk-Padzik A, Kalicinska A, et al. Activity of ozonated water and ozone against Staphylococcus aureus and Pseudomonas aeruginosa biofilms. *Med Sci Monit.* 2011;17:Br339-344.
- Barnes RL, Caskey DK. Using ozone in the prevention of bacterial biofilm forming and scaling. *Water Condition Purif.* 2002;<http://www.prozoneint.com/pdf/biofilms.pdf>.
- Trevisani V, Udell J. American College of Rheumatology (ACR) 2015 Annual Meeting. Abstract 311. 2015. <https://www.medscape.com/viewarticle/854482>.
- Berberi EF, Marculescu C, Sia I, et al. Culture-negative prosthetic joint infection. *Clin Infect Dis.* 2007;45:1113-1119. <http://www.umich.edu/~projbnb/cvr/O2transport.pdf>.
- Chaitidis P, Kreutzer FJ, Gerth C, Janata P, Kuhn H. Impact of intravenous oxygen therapy on the expression of reticulocyte-type 15-lipoxygenase in human volunteers. *Prostaglandins Leukot Essent Fatty Acids.* 2004;71:271-276.
- Schmidt H. Regelsberger's intravenous oxygen therapy--an interpretation of results in practice from a biochemical and physiological point of view. *Forsch Komplementarmed Klass Naturheilkd.* 2002;9:7-18.
- Stichtenoth DO, Kreutzer FJ, Gutzki FM, Tsikas D, Nowak V, Frolich JC. Effects of intravenous oxygen on prostacyclin and thromboxane formation in patients with peripheral occlusive arterial disease. *Prostaglandins Leukot Essent Fatty Acids.* 2001;65:211-214.
- Thom SR. Hyperbaric oxygen: its mechanisms and efficacy. *Plast Reconstr Surg.* 2011;127 Suppl 1:131S-141S.
- Cobo J. Private communication. 2016-01-20.
- Ehrlich G, Demeo P, Costerton J, Winkler H. Culture negative orthopedic biofilm infections. <https://pdfs.semanticscholar.org/0892/38e75c85a603be988658e50759c984a38aa3.pdf>2012.
- Spellberg B, Guidos R, Gilbert D, et al. The epidemic of antibiotic-resistant infections: a call to action for the medical community from the Infectious Diseases Society of America. *Clin Infect Dis.* 2008;46:155-164.